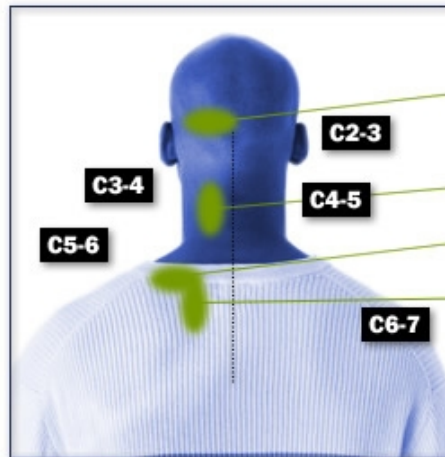


### FIBROMYALGIA & FACET REFERRAL PATTERNS

Do you have the correct diagnosis?

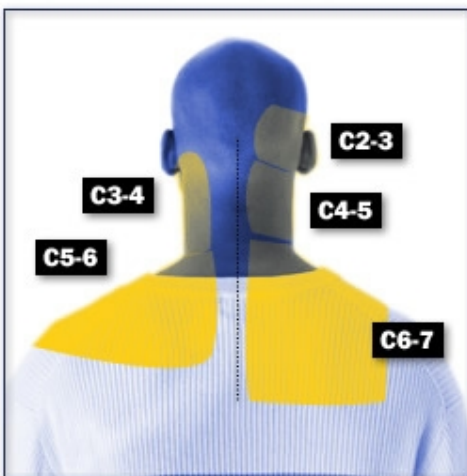
#### FIBROMYALGIA



Upper spine location of tender points (Wolfe 1990)

1. Suboccipital muscle insertions at occiput
2. Lower cervical paraspinals
3. Trapezius at midpoint of the upper border
4. Supraspinatus at its origin above medial scapular spine

#### FACET REFERRAL PATTERNS



#### FIBROMYALGIA / FACET REFERRAL PATTERNS OVERLAP

